

Research Article

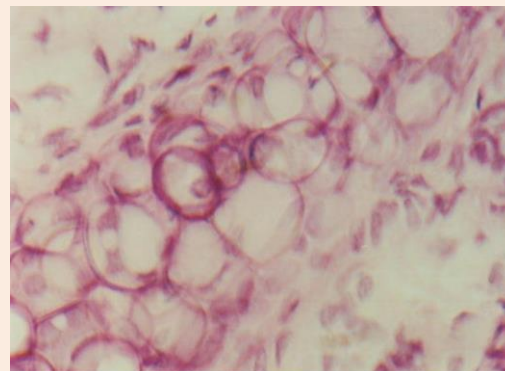
Histopathological Observations of Anacardic Acid – A Phytotoxin Responsible For Occupational Dermatitis

T. Helga Premi and K. Jayaprakash*

Department of Biotechnology, Karpaga Vinayaga College of Engineering and Technology,
Chinnakolambakkam 603308, Kancheepuram District, Tamil Nadu, India.

Abstract

The anacardic acid of cashew nut shell exposure causes phytodermatitis among workers in cashew nut industries. The above said acid was extracted and purified from the nut shell of cashew nut *Anacardium occidentale*. The effect of anacardic acid on epidermal tissue was studied by Swiss mice species. The histopathological examination of serial section prepared from the ear lobe epidermal layer of experimental animal with prior exposure. The results have shown various significant cell injuries as that of pre skin cancerous state. The above results are discussed with earlier literature.



Keywords: *Dermatitis due to anacardic acid; occupational skin dermatitis; Anacardic acid and phyto dermatitis*

***Correspondence**

K. Jayaprakash,
Email: eswarijp@gmail.com

Introduction

Phyto dermatosis is a skin injury due to contact of certain plant and plant derivatives. It is a matter of interesting subject, to study the effect of such plant principles on human subjects. This kind of dermatosis may be either due to direct contact or due to the occupational exposure. The plant *Anacardiaceae* family member *Anacardium occidentale* is one such plant having skin irritable substances in their fruit shells. The fruit shell has a mono phenol with 15 Carbon, the cardanol and a bi phenol with 15 Carbon. The phenols of this plants caused allergic reactions. Among these substances the anacardic acid has high potential irritating property and cause caustic effect[4-6]. Much research has already been carried out on the chemical property of these natural organic chemical species. However there is no substantiated clear study on the cross reaction of anacardic acid in human skin injuries.

The working force engaged in cashewnut cottage industries is continuously exposed with anacardic acid of *Anacardium occidentale*. This contact is due to the peeling of nut shell from the fruit while they were working in the said industries. Normally high number of women labours is engaged in these industries. They have been developed mild to severe contact dermatosis in their fingers and arms. This is the common seen witnessed in the area where cluster of cashew nut cottage Industries are located. In Tamilnadu, districts of Cuddalore and Tanjore have many small scale cottage industries. Since cashew nut tree growing is the major agricultural activity. Many working women's habitat in this area has the symptoms of this occupational hazard. They are using castor oil as a counter irritant in a crude manner, which is also known to cause certain skin allergic reactions.

Occupational Health and Industrial safety is a matter of serious concern. The minds of workers should have an attention on these measures, In India, a large section of the workers are employed in industries. The working communities of these industries are unaware about their occupational safety at their working environment. So as also

they do not know the implementation of safety regulations and devices. Besides the poor implementation of labour welfare enforcements also contribute fuel to fire. A healthy worker contributes more to the company and safe environment makes worker feel secure. This is a main component, which influences the production and profit in turn national economic sustenance. A comprehensive occupational health and industrial safety measures can prevent occupational diseases with increasing demands on productivity and to cut down costs on labor. Cashew nut cottage industries are one such organization, where lack of awareness on occupational hazards due to the peeling and roasting of kernels as described in the preceding paragraph. Majority of the labor engaged in these industries are illiterates, socially backward and women in gender. The present study has been an attempt to know the degree of skin damage due to the exposure of anacardic acid in animal model.

Materials and Methods

The materials of present investigation were the extraction of anacardic acid and its different dilutions derived from the plant *Anacardium occidentale*. The said acid irritant of natural origin was extracted and purified as per the method outlined by Nikorn Sornprom[8].

The cashew nut shells were collected from the tree growers. They were grinded into fine particles and dried at 60°C for 12 hours. 10 g of the above powder was added with 40 ml of ethanol as a solvent. With the help of hot plate magnetic stirrer the anacardic acid was extracted from the solvent ethanol. Then the extract was added with 2.5 g calcium hydroxide to prepare calcium anacardate. The pure form of anacardic acid was eluted by column deionization and was tested by HPLC. The stock solution of anacardic acid was maintained for animal exposure studies.

Two groups of Swiss mice consisting of 10 numbers in each group were purchased from animal house of TamilNadu Veterinary College, Chennai. The obtained anacardic acid will be dissolved in Dimethyl Sulfoxide in the following concentration such as 100 mg/ml, 60 mg/ml, 20 mg/ml. 0.2 ml of this solution will be applied on the pinna region of the test mice (T1, T2, T3) in a regular time interval of 24 hrs. One rat was kept as control (C). The exposed tissues were dissected out by making small incision on the experimental tissue site, with the intervals of 5 days, 10 days, 15 days after the exposure of anacardic acid. The tissue specimens were subjected for the histopathological observations. Routine procedures of micro technique was followed for the slide preparation and stained with hemotoxylin and eosin. The sections were observed under epifluorescent microscope (NIKON Eclipse E400).

Results and Discussion

The results of histopathological examinations on the serial sections of dermal tissue of Swiss mice ear lobe exposed with anacardic acid have revealed many histological changes in the epidermal cells and their arrangements, while comparing with corresponding tissue section slides from matching controls. There is an evidence of inflammation infiltration (Fig.1a). The close observations on the tissue sections exhibited several nests of atypical cells with melanin pigmentation (Fig.1b). There is an indication of pagetoid involvement in epidermis (Fig.1c). In many locations there is a loss of granular layer, cell adhesion and thickening of epidermis (Fig.1d). The above histopathological results would presume that the condition of tissue damage suggesting hyperplasia and chronic inflammatory infiltrate. There are large flattened squamous cells (Fig.1d).

The degree of severity of cell injuries is directly proportional to the exposure periods. The cellular damage is much more significantly pronounced in the section obtained from the group of animals exposed with anacardic acid after 15th day. There are evidences of cell necrosis and development of preconditioned stages of *intertrigo* and *keratosis* (Fig.1e).

The foregoing histopathological examinations would unambiguously assume the cause of dermatitis and the nature of cell injuries due to the phyto allergen anacardic acid from *Anacardium occidentale*. From this present study

by animal model it may be extrapolated the nature of occupational dermatitis among the women workers engaged in cashew nut cottage industries.

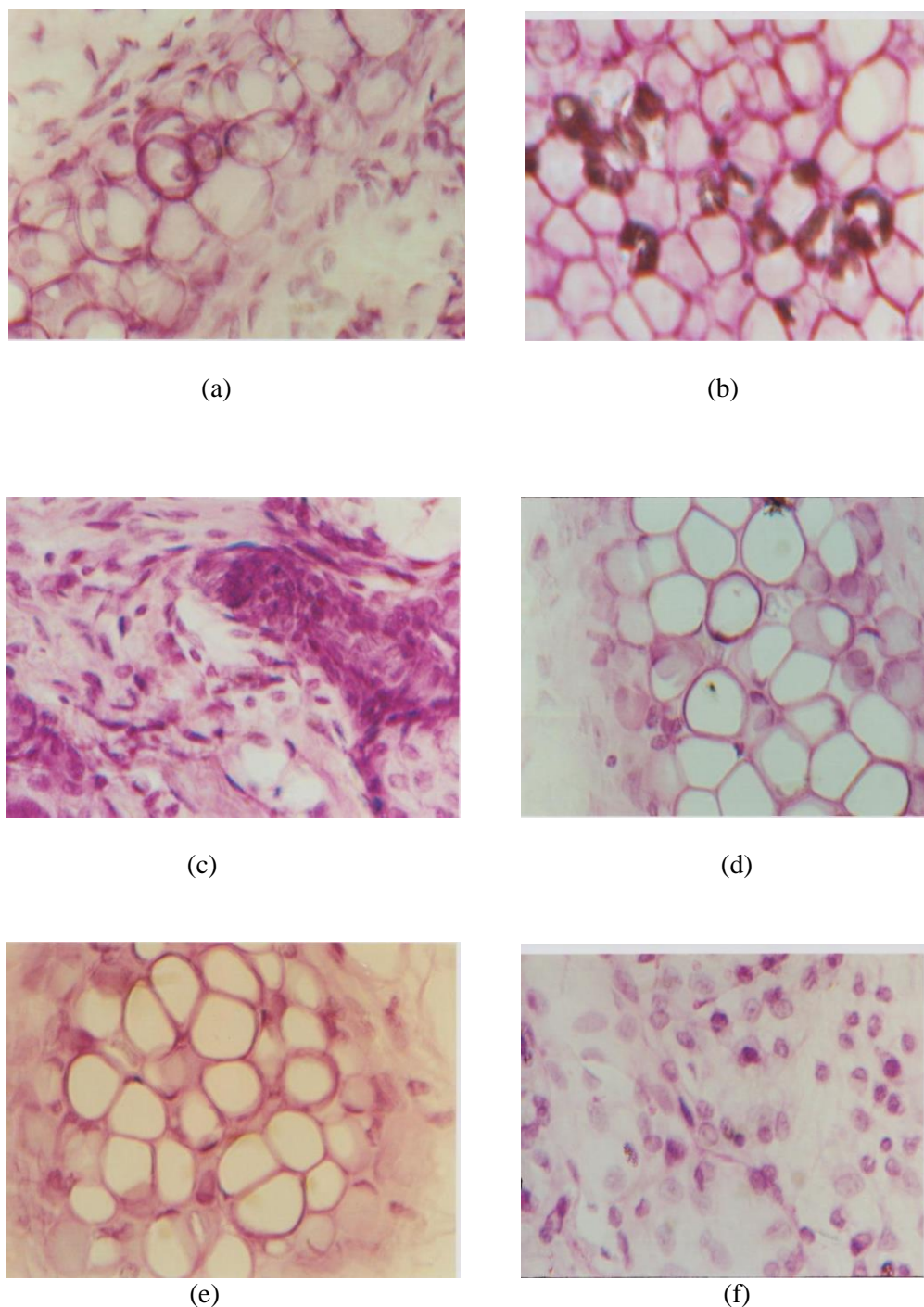


Figure 1 Microphotographs of ear lobe skin of Swiss mice exposed with 100 μ l of anacardic acid viewed under epifluorescence microscope (NIKON Eclipse E 400) stained by acid haemotoxylin and eosin (x 450), where (a) infiltrate inflammation, (b) Melanin pigmentation, (c) Pagetoid involvement, (d) Loss of cell adhesion, (e) Flattened squamous cells, and (f) Necrosis.

Normally the phyto dermatitic occupational skin injuries among workers of cashew nut factories are reversible. However, if the dermal damage is continuous and untreated, the skin injuries may persistent and prone for other severe skin health complications. The present studies on this subject also corroborate with the results of the earlier investigations [1,3].

Conclusions

Workers who handle the cashew nut trees and the shell oil are in danger of acquiring symptoms of the dermatitis within a few hours to several days after initial contact .They experience itching on the parts contacted, and papules followed by vesicles appear superficially in the epidermal layer of the skin. The toxin may be spread from one area of the skin to another, but contrary to popular belief it is not contained in the vesicular fluid. The eruption comes out in crops, and the parts of the skin having the most contact with the irritant are the first areas affected. Sometimes the only lesions are roughness, cracking, and irritation of the fingers [7]. The results of present histopathological skin lesions would suggest the development of *miliaria*, *intertrigo*, *melanomas* and *keratosis*. Kobayashi and his school of thought[2] in their opinions, they reported in their paper that these conditions are pre cancerous and may lead to the development of skin carcinomas. Further it is suggested that the individuals with immunosuppressive condition particularly deficiency of IgE may prone for this dermal skin malignancy.

Therefore it is desirable to undertake much more clear studies with immunological relations. A suitable research on counter irritant against this occupational hazard and preventive measures are underway.

Acknowledgements

The authors are grateful to the Management and Principal of KVCET, Chennai -603 308 for their encouragements and provisions. They are also thankful to the Principal of JJ college of arts and science, Pudukottai to conduct animal experimental studies and institutional animal ethical clearance (JJC/IAEC/2014/01).

References

- [1] Hirao A, Oiso N, Matsuda H, Kawara S and Kawada A., Contact Dermatitis, 2008,59,131.
- [2] Kobayashi H, Takahashi K, Mizuno N, Kutsuna H, Ishii M., Evid Based Complement Alternat Med, 2004, 1, 145.
- [3] Maje HA and Freedman DO., J Travel Med, 2001, 8, 213.
- [4] Nag PK, Kumar S, Tiwari RR and Patel S., Occupational Skin Diseases, Envis Nioh, 2010, 5, 1.
- [5] Oka K, Saito F, Yasuhara T and Sugimoto A., Contact Dermatitis, 2004,51, 292.
- [6] Reis VMSD, Anais Brasileiros de Dermatologin, 2010, 85, 479.
- [7] Rajumoham A, Munich Personal RePEc Archive, 2009, 37712, 14.
- [8] Sornprom N, www.research.rdi.ku.ac.th.
- [9] Goon ATJ and Goh CL., Indian J Dermatol, 2011, 56,707-710.
- [10] Diogenes MJN, Morais SM and Carvalho FF., Contact dermatitis, 2006, 35,114-115.
- [11] Beck MH and Williams JDL., Kanerva's Occupational Dermatology, 2012, 3, 128-129.

© 2014, by the Authors. The articles published from this journal are distributed to the public under “Creative Commons Attribution License” (<http://creativecommons.org/licenses/by/3.0/>). Therefore, upon proper citation of the original work, all the articles can be used without any restriction or can be distributed in any medium in any form.

Publication History

Received	April 2014
Revised	May 2014
Accepted	May 2014
Online	May 2014